

Skin scars and wrinkles temporary camouflage in dermatology and oncoesthetics: focus on acetyl hexapeptide-8

B. Palmieri^{1,2}, A. Noviello³, V. Corazzari^{2*}, A. Garelli⁴, M. Vadala²

¹Department of General Surgery and Surgical Specialties, University of Modena and Reggio Emilia Medical School, Surgical Clinic, Modena, Italy; ²Second Opinion Medical Network, Modena, Italy; ³Oncology Training International Oncology Esthetics (OTI), Milan, Italy; ⁴Plastic and reconstructive surgery, Roma, Italy

Abstract

Objective. The aim of study is to evaluate the aesthetic outcome of specific formulated cosmeceutical product to mask and reduce the appearance surgical scars or unappealing skin tags in chronic diseases, such as cancer.

Methods. In a spontaneous, anecdotal, retrospective study, 26 patients with skin disorders appealed to Second Opinion Medical Network (Modena, Italy), required masking and improving the skin appearance. To evaluate the aesthetic improvement of skin imperfections, a gel-cream containing 10% of acetyl hexapeptide-8 (registered trademark Argireline®) was selected, that can be applied directly upon the lesion, followed by a light massage in the treated area for a few minutes.

Results. The skin quality parameters (hydration, elasticity, sebum), photographs and investigators clinical assessment have been performed before and after the treatment and demonstrated that this cream significantly improved the skin values and the self-image expectation of each patient. No allergic reactions were documented during the period treatment.

Conclusions. The topical administration of this cosmeceutical cream is a safe and effective alternative to the invasive procedures, to improve the quality of life in patients with some skin disorders such as cancer, surgical scars, hidradenitis, aging wrinkles. *Clin Ter 2020; 171 (6):e539-548. doi: 10.7417/CT.2020.2270*

Key words: scars, topical treatment, acetyl hexapeptide-8, cosmeceutical cream, oncological treatment, quality of life

Introduction

Scar formation is the consequence of the deep dermis reaction to skin traumas of various origin (1). The activation of hemostasis is the very first step followed by inflammation, cell proliferation and new matrix deposition (2). This allows the reconstruction and remodeling of the tissue to restore the mechanical and functional characteristics of the previously intact skin. The scar healing is a multistep process, mobilizes and activates different cells, such as endothelial cells, integrins, fibroblasts at specific steps and involving local and systemic endogenous and exogenous mechanisms (1, 2). The wound repair is individually tailored and different scar

types (e.g. atrophic, hypertrophic scar or keloid) (reported in Tab. 1), confirm that the process depends by individual genetics, age, anatomic topography of the lesions, ethnicity, etiology, single or multiple causes of trauma, complications along of the healing steps, etc (1). Some exogenous factors are also involved, such as exposure to solar radiation, life-style (smoking, alcohol, food, etc.) and professional activity (1). Because of the collagen strands synthesis bridging the wound margins and promoting epidermal cells centripetal shifting to fill the chronic skin gap, the scar is always variably visible and cannot totally be erased (3, 4).

The different approaches to treat scars include natural methods, drug therapies, para-surgical therapies and surgery (3, 5-9). Despite the advanced medications and advices adopted by surgeons, caregivers and patients during the perioperative and postoperative periods to achieve the best aesthetic outcome, further surgical, chemical or laser revision is required to reach the optimal outcome (6).

In the context of oncological therapies, it is necessary to consider the effects on wound healing of chemotherapy and radiotherapy as well as surgical instruments used intra-operatively including laser radiofrequencies ultrasounds, cold knives etc. (10). Postsurgical chemotherapy is always a chemical prolonged trauma to the surgically injured tissues, involving the skin and the skin's appendages, such as hair and nails. Depending on the drug type, the effect can be mild swelling, local irritation, inflammation or even actual tissue necrosis (10). Scars from skin cancer surgery, especially the facial ones, can be prominent and not easily relieved by make-up (11). The marks often show hypopigmentation, hyperpigmentation, neovascularization or diminished pore structures compared to the surrounding skin (11).

Olsson et al. (12) explored the extent to which scars affect adolescents and adults post-cancer treatment. They developed emailed a study-specific questionnaire with items on psychosocial health, body image and sexuality, fertility, education, work, and leisure, to teenage and young adults cancer survivors and matched controls in Sweden (12). The relative risk of feeling less attractive due to scars was higher both for female and male cancer survivors compared to controls. The feeling of attractiveness was negatively

Correspondence: Veronica Corazzari, Network del Secondo Parere, Via Saliceto Panaro 5, 41122 Modena, 0598303683.
E-mail: verocoraz@outlook.it

Table 1. Synoptic table of scars types

	Description	Predisposing factors	Chronology	Histology	Treatments	Therapeutic effect
Hypertrophic scar	In relief and red, it can be accompanied by itching and pain. Generally, the scar remains within the borders of the original lesion and develops in depth.	Less genetic predisposition and less association with skin pigmentation	It appears usually after surgery, or trauma (linear hypertrophic scar) or a burn (extended hypertrophic scar)	Scar appears with absence of a tongue-like advancing edge underneath normal-appearing epidermis and papillary dermis. No horizontal cellular fibrous band in the upper reticular dermis and no prominent fascia-like fibrous band. There is the presence of well-organized, wavy collagen fibers, type III collagen bundles parallel to the surface of the epidermis; nodules containing myofibroblasts and acid mucopolysaccharide; increase of connective tissue.	- Spontaneous regression - Corticosteroids - Surgery	Overall prognosis is better than keloids, it improves with appropriate surgery and low recurrence following surgical excision
Keloid	Thick, irregular, rounded, with a red-brownish and/or hard colour. Formed by scar tissue, it extends beyond the limits of the original lesion. It develops both in depth and in width.	More established genetic predisposition and more association with skin pigmentation.	Post trauma or it appears spontaneously	Scar appears with a presence of a tongue-like advancing edge underneath normal-appearing epidermis and papillary dermis. Appearance of horizontal cellular fibrous band in the upper reticular dermis and prominent fascia-like fibrous band. The collagen fibers are disorganized, large, and hyalinized types I and type III hypocellular collagen bundles with no nodules or excess myofibroblasts. Finally, there is poor vascularization with widely scattered dilated blood vessels and increased of connective tissue.	-Not spontaneous regression -Silicone based creams - Vitamin E implementation - Massages to make the skin softer	Overall prognosis is worst, often by surgery high recurrence is observed after surgical excision
Atrophic scar	Insufficient amount of tissue to cover the entire wound. Reduced rounded and depressed formation with respect to the surrounding skin.	Result of diseases like acne or chicken pox.	Alteration of the tissue regeneration and insufficient production of new connective tissue fibers.		- Chemical peels - Laser therapy - Exfoliating treatments - Drugs: Benzoyl peroxide, topical retinoids, azelaic acid, isotretinoin	

related to the size of scars in both groups. However, further research on care interventions is needed to reduce, if possible, the impact of scars (12).

Due to the doctor-patient communication gap, most of the patients usually wander around the medical websites looking for proper answers to their health problems. However, their search often becomes compulsive and obsessive and often ambiguous and frustrating (13). Palmieri et al. (14) describe this behavior as the “Web Babel Syndrome” – a psycho-

logical imbalance affecting young and elderly patients, especially those with multiple synchronous diseases who receive from their caregivers heterogeneous and misleading information or advices, including confused, contradictory statements and prescriptions (15). This spontaneous, anecdotal, retrospective study is based on the evaluation of the therapeutic efficacy of a topical product, and its aim is to improve the appearance of scars and skin imperfections, since the camouflage of such imperfections resulting from

surgery or acne can have a long-term aesthetic benefits and improve the quality of life of patients, including their psycho-social state.

Materials and methods

Sample Population

26 volunteers (females) between 23 and 63 years of age (Tab. 2) appealed to our "Second Opinion Medical Consulting Network", Medical Centre (Modena, Italy), because of cutaneous and/or surgical scars/blemishes from chronic diseases such as cancer, hidradenitis, etc.

Second Opinion Network

The Second Opinion Medical Network is a consultation referral web and Medical Office System recruiting suddenly a wide panel of real-time available specialists, to whom any patient affected by any disease or syndrome and not adequately satisfied by the diagnosis or therapy can apply for an individual clinical audit (16). To help patients discontented with their psycho-physical condition, the Second Opinion Network aims to be a useful "problem-solving" support revisiting each diagnostic and therapeutic step and properly re-addressing tailored treatments and prognoses, as well as preventing unnecessary investigational procedures and unhelpful and expensive medical and surgical interventions (17).

Process of application of the product

All the patients were visited and informed during a personal interview, gave their permission, and signed an

informed consent. We selected, as topical treatment, a cosmeceutical gel product, Instant Ageback (Vitayes®, Frankfurt, Germany). It combined with several active ingredients, including water, magnesium aluminum silicate, propylene glycol, sodium silicate, acetyl hexapeptide-8 (reported in Fig. 1), phenoxyethanol, ethylhexylglycerin, caprylyl glycol, CI 16035, each with specific action (Tab. 3).

The product is simple to use with immediate and long-term aesthetic effect: the healthcare professional applies a small amount (rice grain) by dabbing lightly on the desired area to treat. The patient waits for the effect while keeping the face muscles relaxed and after only five minutes, skin blemishes appear visually lessened. It is advisable to apply a moisturizer before proceeding with Vitayes® Instant Ageback.

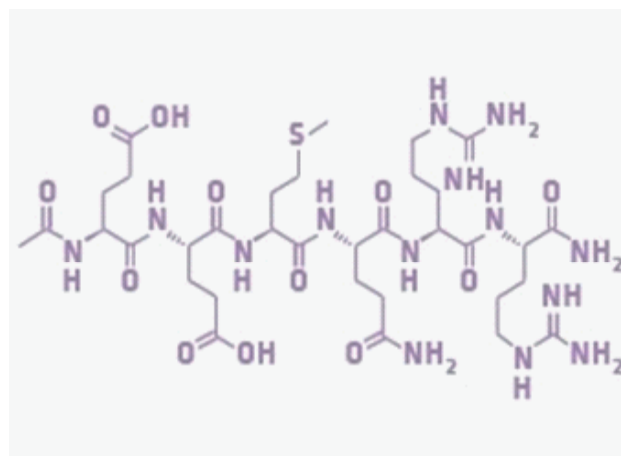


Fig.1. Chemical structure of acetyl hexapeptide-8

Table 2. Clinical cases characteristics.

N. Patients	Gender	Disease	Therapy
12	Female	Adenoid cystic carcinoma	Surgery
1	"	Hidradenitis	Incision and topical creams
10	"	Moles lesions	Surgery
3	"	Aging	Topical creams

Table 3. Functions of raw materials that constitute the topical product.

ACTIVE INGREDIENTS	FUNCTION
Water	Solubilizer
Magnesium Aluminum silicate + Sodium silicate	Instant firming effect
Propylene glycol	Humectant, skin conditioning
Acetyl hexapeptide-8	Long-term anti-aging effect
Phenoxyethanol + Ethylhexylglycerin	Preservative
Caprylyl Glycol	Conditioning of the skin
CI 16035	Dye

10 patients reported scars on the left side of the face and neck, 10 other patients on the right area, while 6 patients on the forehead and chin. The following skin evaluations have been performed:

- Hydration at baseline and after treatment by means of point of care (POCT) DermaLabR USB instrument (Cortex Technologies, Hadsund, Denmark). It has a hydration probe, that is pressed upon the skin and due to the conductance principle, measures the water binding capacity of the stratum corneum (18).
- Elasticity assessment by means of ElastiMeter R (Delfin Technologies, Kuopio, Finland), it measures a stiffness, a physical measure of an object's resistance to change in shape under an external force in N/m. The device consists of a 1 mm length indenter, a reference plate and built-in force sensors. The probe head is quickly pressed against the skin surface with a recommended standard pressure that is displayed on the screen. The indenter induces a constant deformation when the reference plate is in full contact with the skin, and the elasticity is determined by the skin resistance to this deformation (19).
- Skin sebum levels by means of Sebumeter SM 815 (Courage & Khazaka electronic), which in pathological conditions tend to increase.
- Photographic assessment at baseline and after cream application.

Skin parameters were measured on six selected areas: chin, left and right neck, forehead, right and left malar area. The value of hydration ((expressed in microSiemens units (μS)), elasticity (expressed in μS), and sebum (expressed in Sebumeter® units from 0-350, approximated to $\mu\text{g}/\text{cm}^2$ in a certain range) is the arithmetic mean of 3-5 repetitive measures in the same area.

The quality of life (QoL) of each patient was evaluated at baseline and after treatment using the abbreviated form of the medical outcome health survey questionnaire (SF-36). It

measures health-related QoL in eight dimensions: vitality, general health perceptions, physical functioning, physical role functioning, emotional role functioning, social role functioning, bodily pain and mental health. Each scale is scored using norm-based methods, with percentage scores ranging from 0% (lowest or worst response) to 100% (highest or best possible response) (20).

Statistical Analysis

Statistical analysis was performed using GraphPad Prism 7 (GraphPad Software Inc., San Diego, CA, USA). Data were analyzed using an unpaired t-test with Welch's correction. $p < 0.05$ was considered significant.

Results

The evaluated skin parameters significantly decreased in all the patients. 10 patients reported scars on the left side of the face and neck, 10 other patients on the right area, while 6 patients on the forehead and chin. The parameters of hydration, elasticity and sebum levels of the scars of these 3 areas have been measured respect to unaffected skin.

The cosmeceutical gel determined a lifting effect, due to a slight decrease in the hydration levels of the affected area than the surrounding skin. In fact, the hydration of scars ($p < 0.01$) in the left area of the neck and malar area changes from 65,5% to 57%; (respectively pre and post treatment), in right neck and right malar area from 65% to 56% (respectively pre and post treatment); in forehead and chin area from 56% to 52% (respectively pre and post treatment) (Fig.2).

Regard the elasticity, it has been observed a significant ($p < 0.001$) elasticity level of the affected area than the surrounding skin. In fact, elasticity of scars improved from

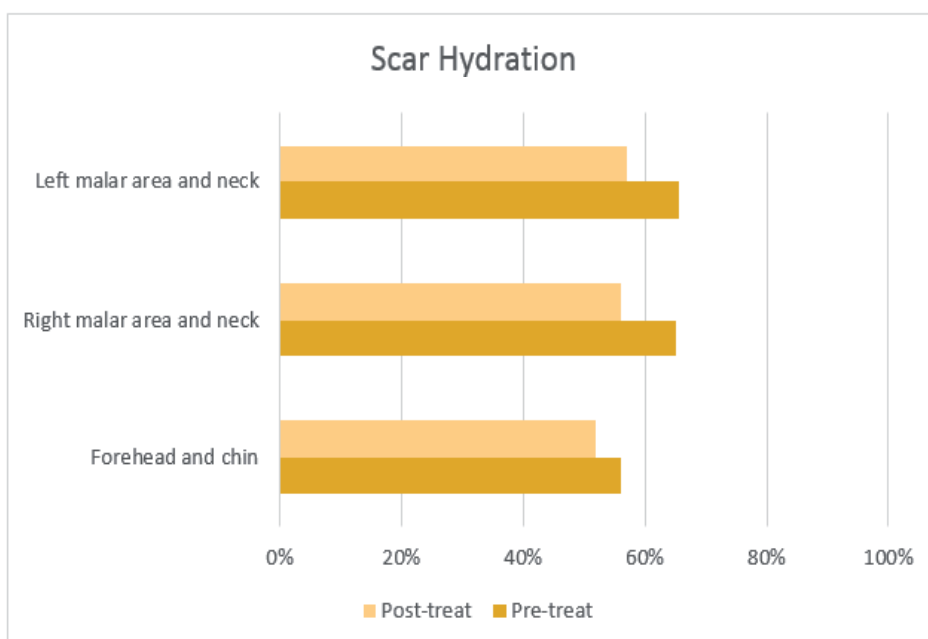


Fig. 2. Scars hydration levels (%) measured before and after treatment in the affected areas

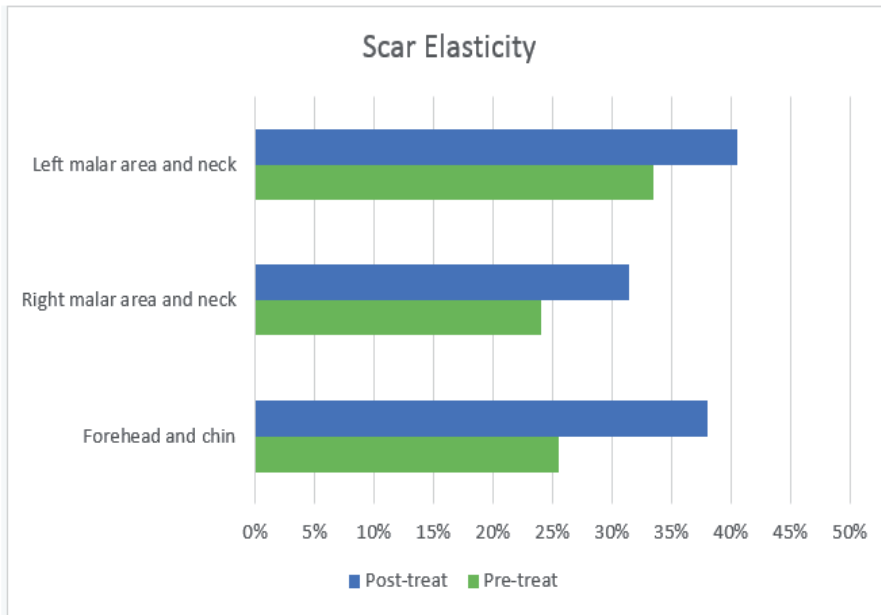


Fig.3. Scar elasticity levels (%) measured before and after treatment in the affected areas

33,5% to 40,5% (respectively pre and post treatment) in left lateral-medial area of the neck and malar area; from 24% to 31,5% (respectively pre and post treatment) in right lateral-medial area of the neck and malar area; and from 25,5% to 38% (respectively pre and post treatment) in forehead and chin area (Fig.3).

In addition, the measured skin sebum levels of the scars evidenced a significant reduction ($p < 0.002$) in all examined skin areas. In the specific, it has been observed a reduced sebum in scars of left neck and in left malar area from 58,5% to 41% (respectively pre and post treatment); in right neck and in right malar area from 65% to 51% (respectively pre and post treatment); in forehead and chin from 90% to 76,5% (respectively pre and post treatment)(Fig.4).

Unretouched photos taken before and after treatment showed a significant improvement of major signs of cancer cutaneous blemishes and scars due a cyst or mole removal surgery (Fig. 5-10). No worsening was reported, only one patient expressed skin hypersensitivity and redness of the affected area within 24 hours after gel application (Fig.6). It has also been observed that topical treatment instantly reduces wrinkles, bags, dark circles, enlarged pores and scars by up to 85%. Furthermore, it firms, drains, refines pores, and ensures flawless skin, showing a lifting effect on atonic skin.

Regard the QoL of patients, the SF-36 questionnaire administered before and after several applications of the cosmeceutical cream, highlighted a significant score in the

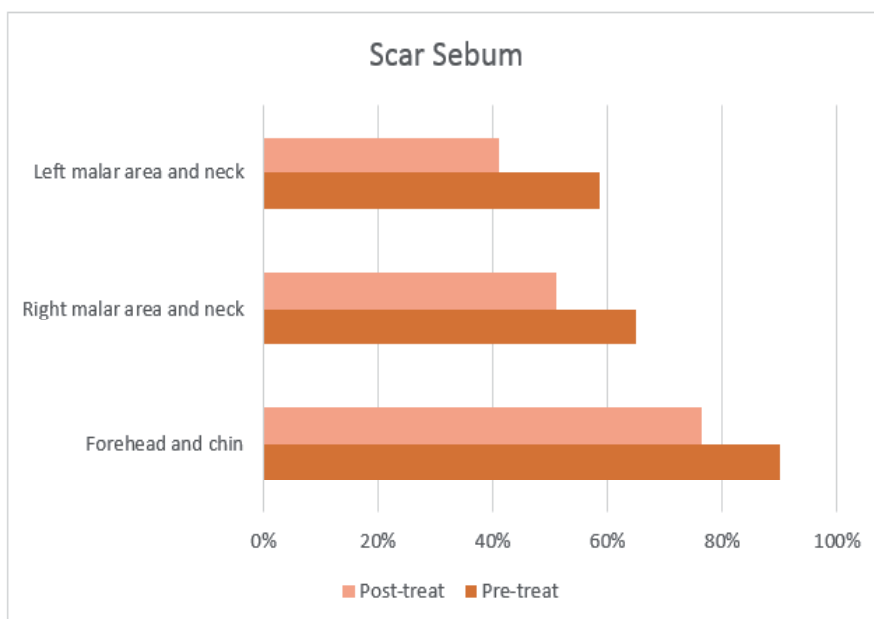


Fig.4. Scar sebum levels (%) measured before and after treatment in the affected areas

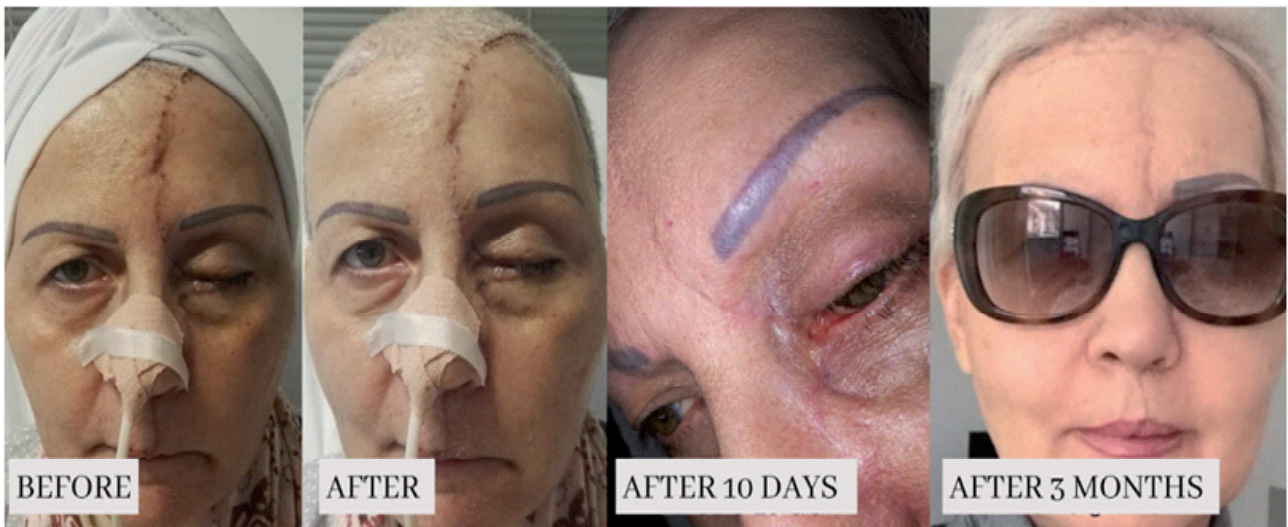

Fig.5. Female, 63 years old, affected by adenoid cystic carcinoma

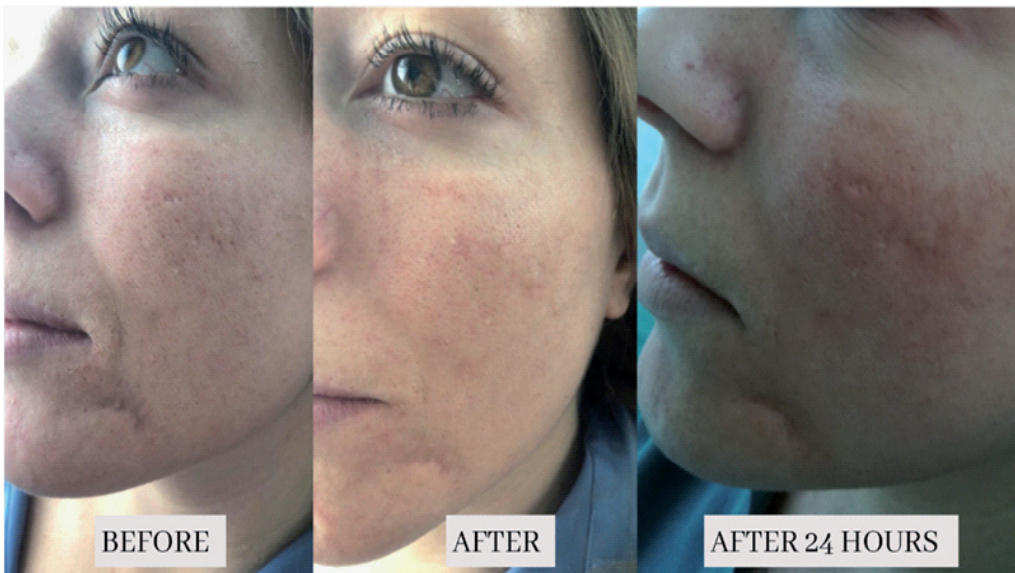

Fig.6. Female, 29 years old, affected by Hidradenitis



Fig.7. Female, 45 years old, affected by mole removed surgically



Fig.8. Female, 40 years old, affected by mole removed surgically

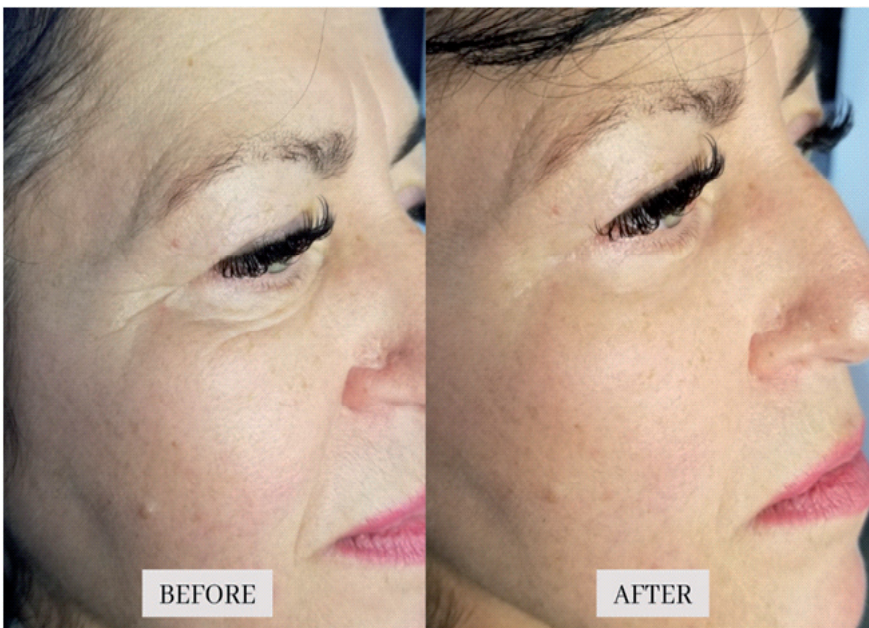

Fig.9. Female, 50 years old, affected by imperfections of aging



Fig.10. Female, 23 years old, affected by mole removed surgically

psychosocial sphere. The main efficacy endpoints were in vitality ($P < 0.03$), in social role functioning ($P < 0.02$) and in mood improvement ($P < 0.03$).

Discussion

Among the different approaches to treat scars, we can mention the complementary therapies, including essential oils (Tea tree oil, lavender etc.) for antibacterial action; Aloe or centella asiatica extract, as anti-inflammatory; allantoin and anthocyanins as antioxidants; Allium Coepa (onion extract) for the kerato-modulating action that reshapes keloids by compression; mineral complexes (petrolatum and silicone) with dermatoprotective effect, etc (5, 21-24). Also topical administration of CBD ointment, without any THC, is a safe and effective non-invasive alternative for improve severe skin chronic diseases and/or outcome scars, especially on inflammatory background (25).

In the medical practice Silicone-based products (sheets, gel or creams), intralesional corticosteroid injections, 5-fluorouracil, bleomycin, interferon, and verapamil are non-invasive methods that modulate the scar appearance (3, 6, 7, 26). Specifically, silicone-based products are particularly used: silicone with its long chain polymers (polysiloxanes), silicon dioxide and volatile components are effective in reducing redness and thickness of the scars. The silicone sheets are effective essentially because they increase the hydration of the stratum corneum, molding a softer and flatter scar; protecting the scar tissue from bacterial contamination and inducing phlogosis and collagen production, modulating the expression of tissue growth factors, balancing the stroma density and collagen strands breakdown (8).

Instead, the para-surgical treatments include cryotherapy, dermabrasion, peeling, filler, laser, radiofrequency (7, 26, 27). Cryotherapy is the rapid delivery of a cryogenic substance but is limited to small scars (since dyschromic outcomes are frequent); dermabrasion is a mechanical smoothing of the skin, usually administered in the intermediate phase together with compression treatments; and lastly peeling is applied with different acid compounds provided of desquamating and kerato-modulating activity (to resist rapid degradation). Fillers are chemically crosslinked mucopolysaccharides based on hyaluronic acid and chondroitin, with bio-stimulating and bio-restructuring properties for the scar, because moisturize mesenchymal tissues (28, 29). Lipofilling is another method currently used, that follows the action mechanism of common fillers: lipofilling requires availability of autologous adipose tissue with or without stem cells supplement to improve scar quality (30) while filler uses mainly cross linked hyaluronic acid.

Several studies reported also pulsed dye laser treatment, non-ablative fractional laser resurfacing, ablative fractional laser resurfacing, microneedling and fractional needle radiofrequency, as skin treatment, either in monotherapy or in combination (6, 27, 31-36). The laser therapy is mainly used in the oncological surgical scars, acne scars and skin-aging (27, 31, 36, 37). The results vary according to the different laser wavelengths, power and administration protocol and standardization are quite difficult (31).

In a study of 2016, Svolacchia et al. (26) investigated the effectiveness of dermal autologous micrografts to improve pathological scars. He used a new clinical practice called Rigenera Protocol to obtain autologous micrografts which were in turn injectable in the patients. These micrografts were composed of mesenchymal stem cells and verified restoration of the structural layers immediately below the epidermis and a horizontal realignment of collagen fibers in the papillary dermis (26).

Other skin method is the surgery, with total or partial scar excision, that can be used to change the position, width or shape of the scar and to decrease the tension of a scar, improving the functionality of the affected area (4).

In this anecdotal, spontaneous, observational study, was found a slight decrease in skin hydration levels and a clear reduction in sebum levels while was recorded an increase in skin elasticity levels. As a result, wrinkles and scars are attenuated in the affected area, improving the psychological frustrations and discomfort of the patients. These effects are due to synthetic acetyl hexapeptide-8 that is the main active substance contained in Vitayes® Instant Ageback (Fig. 1). It is a molecular weight of 889 Dalton patterned after the N-terminal end of the protein Synaptosomal-associated protein 25 (SNAP-25), that is part of the synaptosome, or the structure responsible for the release of acetylcholine (38, 39). Acetyl hexapeptide-8 competes with SNAP-25 binding to it as agonist of the vesicle-associated membrane protein (VAMP) with subsequent inhibition of neuronal exocytosis preventing the attachment protein of receptor (SNARE) complex (39). As a result, acetylcholine (40) is not secreted into the vesicles, and the absence of cholinergic effect upon striated muscles in example of the facial expression induces relaxation with an action mechanism similar to botulinum toxin, but without any risk of toxicity, and very low transdermal diffusion after epicutaneous administration (39, 40). Only 0.22% of the total amount is permeated through the skin and retained within stratum corneum, and only the 0.01% of the peptide is through in the epidermis (41). To overcome the problem, several research groups have attempted to enhance transdermal delivery of acetyl hexapeptide-8 by optimizing the formulations. For instance, Hoppel et al. (42) showed a clear superiority of water-rich water-in-oil-in-water (W/O/W) and oil-in-water (O/W) emulsions over oil-rich water-in-oil emulsion (W/O) emulsions, due to increased absorption of water-rich emulsions into the skin (39, 42). Vitayes® Instant Ageback is combined with water, magnesium aluminum silicate, propylene glycol, sodium silicate, acetyl hexapeptide-8, phenoxyethanol, ethylhexylglycerin, caprylyl glycol, CI 16035. Therefore this molecular combination achieves contemporarily a double effect: relaxation of the skin surface due to mimic muscles block; epidermal fluid embedding (interstitial water uptake and temporary sequestration) with increased smoothness of the surface and reduced appearance of scars or skin irregularities (pores, granuloma nodules etc.).

Strengths and limitations of the study

This study can be considered an innovative contribution in the field of dermatological cosmetics. The product can

be useful for patients with different problems: from surgical scars to imperfections, due to aging or skin disorders such as acne and hydrosadenitis. Furthermore, the application of this topical active principle did not show any particular adverse effects.

On the other hand, the major limitation of the present study was a small number of clinical cases. Further research, also in male gender, with the aim to evaluate any differences with the female gender in terms of skin responses and psychosocial impact, are needed.

Conclusions

The clinical results suppose that the active principle of Vitayes® Instant Ageback, acetyl hexapeptide-8, modifies the surface appearance of the skin not only reducing the wrinkles and minor skin folds holes and irregularities, but masking also the surgical scars with temporal smoothing and lightening epidermal surface and mimicking the effect of botulinum toxin.

The treatment is quite safe and comfortable except some perceived slight dryness of the surrounding skin. The mechanism of this effect is well explained by the skin parameters measured on our treated patients: a slight reduction of skin hydration reduces the scar prominence and visibility; on the other hand the increase in elastic skin response amplifies the Acetyl hexapeptide-8 induced skin relaxation, producing a smoother and brighter appearance of the whole face surface and great patient satisfaction even if aware that the improvement will be lasting 4-8 hours.

Finally, the need to carry out a future clinical trial is underlined, with a blind application of the product in two different groups. Next Acetyl hexapeptide-8 administration study can also give adequate information about the long-term benefits of the treatment, namely the putative steady improvement of the skin textures and of the scar definite camouflaging effect.

Actually, the use of Vitayes Instant Ageback is recommended in the short term because of the high patient compliance, the absence of side effects and the optimal tolerability also when administered over very sensitive skin surfaces. Intolerance to the product in fact has been rarely observed in cancer patients with visible scarrings after radio/chemo therapy, and also in young girls affected by acne eruptions and scars.

In all these patients, the camouflage was very effective and socially appreciated.

Declarations

Acknowledgement: None

Financial Disclosure or Funding: Not applicable.

Conflict of Interest: None declared.

Institutional Review Board Approval: Second Opinion Medical Network, Modena, Italy.

Data Availability: The authors declare that data supporting the findings of this study are available.

All procedures performed were in accordance with the 1964 Helsinki declaration and its later amendments or comparable ethical standards.

References

- Gauglitz GG, Potschke M, T. Clementoni, (Therapy of scars with lasers). *Hautarzt*, 2018; 69(1):17-26
- Wolfram D, et al. Hypertrophic scars and keloids--a review of their pathophysiology, risk factors, and therapeutic management. *Dermatol Surg*, 2009;35(2):171-81
- Ghazawi FM, et al. Insights into the Pathophysiology of Hypertrophic Scars and Keloids: How Do They Differ? *Adv Skin Wound Care*, 2018; 31(1):582-595
- Garg S, Dahiya N, Gupta S, Surgical scar revision: an overview. *Journal of cutaneous and aesthetic surgery*, 2014; 7(1): 3-13
- Fang QQ, et al. The Effectiveness of Topical Anti-scarring Agents and a Novel Combined Process on Cutaneous Scar Management. *Curr Pharm Des*, 2017;23(15):2268-2275
- Eilers RE, Jr, et al. A Combination Approach to Surgical Scars. *Dermatol Surg*, 2016; 42 Suppl 2:S150-6
- Gauglitz GG, et al. Hypertrophic scarring and keloids: pathomechanisms and current and emerging treatment strategies. *Mol Med*, 2011;17(1-2):113-25
- Mustoe TA, et al. International clinical recommendations on scar management. *Plast Reconstr Surg*, 2002; 110(2):560-71
- Leventhal D, Furr M, Reiter D. Treatment of keloids and hypertrophic scars: a meta-analysis and review of the literature. *Arch Facial Plast Surg*, 2006; 8(6):362-8
- DeHaven C. Chemotherapy and radiotherapy effects on the skin. *Plast Surg Nurs*, 2014; 34(4):192-5
- Cohen JL. Minimizing skin cancer surgical scars using ablative fractional Er:YAG laser treatment. *J Drugs Dermatol*, 2013; 12(10):1171-3
- Olsson M, et al. Self-Perceived Physical Attractiveness in Relation to Scars Among Adolescent and Young Adult Cancer Survivors: A Population-Based Study. *J Adolesc Young Adult Oncol*, 2018; 7(3):358-366
- Palmieri BLC, Vadalà M, The "Second Opinion Medical Network". *Int J Pathol Clin Res* 2017; 3:056
- Palmieri B, et al. (Second opinion clinic: is the Web Babel Syndrome treatable?). *Clin Ter* 2011; 162(6):575-83
- Palmieri B, Iannitti T. The Web Babel syndrome. *Patient Educ Couns*, 2011; 85(2):331-3
- Wunsch A, Palmieri B. The rôle of second opinion in oncology: an update. *European Journal of Oncology*, 2014; 18(3): 117-120
- Di Cerbo A, Palmieri B. The economic impact of second opinion in pathology. *Saudi Med J*, 2012; 33(10):1051-2
- Laurino C, Palmieri B, Coacci A. Efficacy, Safety, and Tolerance of a New Injection Technique for High- and Low-Molecular-Weight Hyaluronic Acid Hybrid Complexes. *Eplasty*, 2015; 15:e46
- Iivarinen JT, Korhonen RK, Jurvelin JS. Experimental and numerical analysis of soft tissue stiffness measurement using manual indentation device--significance of indentation geometry and soft tissue thickness. *Skin Res Technol*, 2014; 20(3):347-54
- Palmieri B, Laurino C, Vadalà M. Spontaneous, anecdotal, retrospective, open-label study on the efficacy, safety and

- tolerability of cannabis galenical preparation (Bedrocan). *Int J Pharm Pract*. 2019; 27(3):264-270. doi:10.1111/ijpp.12514
21. Bylka W, et al. Centella asiatica in dermatology: an overview. *Phytother Res*, 2014; 28(8):1117-24
 22. Feily A, Namazi MR. Aloe vera in dermatology: a brief review. *G Ital Dermatol Venereol*, 2009; 144(1):85-91
 23. Prager W, Gauglitz GG. Effectiveness and Safety of an Overnight Patch Containing Allium cepa Extract and Allantoin for Post-Dermatologic Surgery Scars. *Aesthetic Plast Surg*, 2018; 42(4):1144-1150
 24. Yeh LC, Gonzalez N, Goldberg DJ. Comparison of a novel wound dressing vs current clinical practice after laser resurfacing. *J Cosmet Dermatol*, 2019; 18(4):1020-1024
 25. Palmieri B, Laurino C, Vadalà M. A therapeutic effect of cbd-enriched ointment in inflammatory skin diseases and cutaneous scars. *Clin Ter*. 2019 Mar-Apr;170(2):e93-e99. doi: 10.7417/CT.2019.2116. PMID: 30993303
 26. Svolacchia F, et al. An innovative regenerative treatment of scars with dermal micrografts. *J Cosmet Dermatol*, 2016; 15(3):245-53
 27. Sadick NS, Cardona A. Laser treatment for facial acne scars: A review. *J Cosmet Laser Ther*, 2018; 20(7-8):424-435
 28. Ramos-E-Silva M, et al. STYLAGE®: a range of hyaluronic acid dermal fillers containing mannitol. Physical properties and review of the literature. *Clinical, cosmetic and investigational dermatology*, 2013; 6:257-261
 29. Khunmanee S, Jeong Y, Park H. Crosslinking method of hyaluronic-based hydrogel for biomedical applications. *Journal of tissue engineering*, 2017; 8:2041731417726464-2041731417726464
 30. Gotland N, et al. (Treating scars with lipofilling). *Ugeskr Laeger*, 2018; 180(26)
 31. Magnani LR, Schweiger ES. Fractional CO2 lasers for the treatment of atrophic acne scars: a review of the literature. *J Cosmet Laser Ther*, 2014; 16(2):48-56
 32. Togsverd-Bo K. Early laser intervention for improved appearance of surgical scars. *Br J Dermatol*, 2019; 180(1):25
 33. Lee Y, Kim W. Combination laser treatment for immediate post-surgical scars: a retrospective analysis of 33 immature scars. *Lasers Med Sci*, 2017; 32(5):1111-1119
 34. Karmisholt KE, et al. Laser treatments in early wound healing improve scar appearance: a randomized split-wound trial with nonablative fractional laser exposures vs. untreated controls. *Br J Dermatol*, 2018; 179(6):1307-1314
 35. Orringer JS, et al. Molecular mechanisms of nonablative fractionated laser resurfacing. *Br J Dermatol*, 2010; 163(4):757-68
 36. Ansari F, Sadeghi-Ghyassi F, Yaaghoobian B. The clinical effectiveness and cost-effectiveness of fractional CO2 laser in acne scars and skin rejuvenation: A meta-analysis and economic evaluation. *J Cosmet Laser Ther*, 2018; 20(4):248-251
 37. Qian H, et al. Treatment of acne scarring with fractional CO2 laser. *J Cosmet Laser Ther*, 2012; 14(4):162-5
 38. Wang Y, et al. The anti-wrinkle efficacy of acetyl hexapeptide-8, a synthetic hexapeptide, in Chinese subjects: a randomized, placebo-controlled study. *Am J Clin Dermatol*, 2013; 14(2): 147-53
 39. Lim SH, et al. Enhanced Skin Permeation of Anti-wrinkle Peptides via Molecular Modification. *Sci Rep*, 2018; 8(1):1596
 40. Blanes-Mira C, et al. A synthetic hexapeptide (Acetyl hexapeptide-8) with antiwrinkle activity. *Int J Cosmet Sci*, 2002; 24(5):303-10
 41. Kraeling ME, et al. In vitro skin penetration of acetyl hexapeptide-8 from a cosmetic formulation. *Cutan Ocul Toxicol*, 2015; 34(1):46-52
 42. Hoppel M, et al. Topical delivery of acetyl hexapeptide-8 from different emulsions: influence of emulsion composition and internal structure. *Eur J Pharm Sci*, 2015; 68:27-35